



Erucism in New Zealand: exposure to gum leaf skeletoniser (*Uraba lugens*) caterpillars in the differential diagnosis of contact dermatitis in the Auckland region

José Derraik

Abstract

There are no indigenous caterpillars known to be associated with erucism, but the recently established gum leaf skeletoniser (*Uraba lugens*) has venom-containing spines that cause adverse reactions in humans. Symptoms are usually characterised by a stinging sensation, followed by itching and the formation of wheals. Exposure to *U. lugens* should be considered by medical practitioners in the differential diagnosis of contact dermatitis in the Auckland region.

Introduction, biological notes, and distribution

‘Erucism’ is the term generally used to refer to the adverse reactions resulting from contact with urticating caterpillars, the larval forms of the insect order Lepidoptera (moths and butterflies).^{1,2} Although erucism is a relatively common public health problem throughout the world,¹ there are no indigenous species of Lepidoptera in New Zealand whose caterpillar is known to cause adverse reactions in humans (Brian Patrick, Otago Museum, personal communication; 2006).³ As a result, erucism has never been a human health issue in this country, and is therefore a condition somewhat unknown to local medical practitioners.

The situation has changed however, since the establishment of the gum leaf skeletoniser *Uraba lugens* Walker (Lepidoptera: Nolidae), an Australian moth whose caterpillar feeds on the foliage of gum trees (*Eucalyptus*) and other closely related genera.⁴ The younger larvae avoid feeding on the oil glands and veins found in the leaves, which are consequently ‘skeletonised’.³ More mature larvae will however eat the whole leaf.³

Uraba lugens is a significant pest for *Eucalyptus* forestry. Infestation by *U. lugens* may kill young trees if there is repeated defoliation.⁵ This process on larger trees may reduce wood production for several seasons.⁶ Outbreaks of this species seem to periodically occur in natural forests in Australia, but these eventually recover, even though defoliation can be severe.⁷

Uraba lugens was first discovered in New Zealand in 1992, and it is now firmly established in the Auckland region, over an area of at least 20,000 ha.⁴ Due to its wide distribution, eradication was deemed to be not feasible.⁸ *Uraba lugens* is now the focus of a long-term management programme aiming particularly at filling current knowledge gaps and controlling the existing population.⁸


The approximate distribution of *U. lugens* currently goes as far north as Takapuna and as far south as the Bombay Hills, including the area between the Hunua Ranges in the east and the Manukau Heads and Waitakere Ranges in the west.⁷ The highest density

of this organism seems to occur in southwest Auckland.⁹ Results from climatic models indicated that *U. lugens* could potentially establish throughout New Zealand. To date, the population is not known to be established outside the Auckland region, but specimens have recently been captured in pheromone traps in Katikati (Bay of Plenty) and Warkworth (Northland).¹⁸

The Auckland populations of *U. lugens* have two generations per year (bivoltine), with larvae usually present from January to March (summer) and May to October (winter).¹⁰ *Uraba lugens* caterpillars vary in length from 1 to 25 mm depending on the stage of development.³ There are between 11 and 13 larval stages.^{4,5}

Uraba lugens are extremely hairy caterpillars with yellow and brown markings, and when mature they retain the head capsules of previous instars that are pushed up to top of the head, which makes *U. lugens* easy to identify (Figure 1).⁵ Each body segment of the larvae has 10 tubercles, four of which are located dorsally and have short, stiff, brown-tipped bristles that are hollow and contain venom that can be injected into the human skin upon contact.³

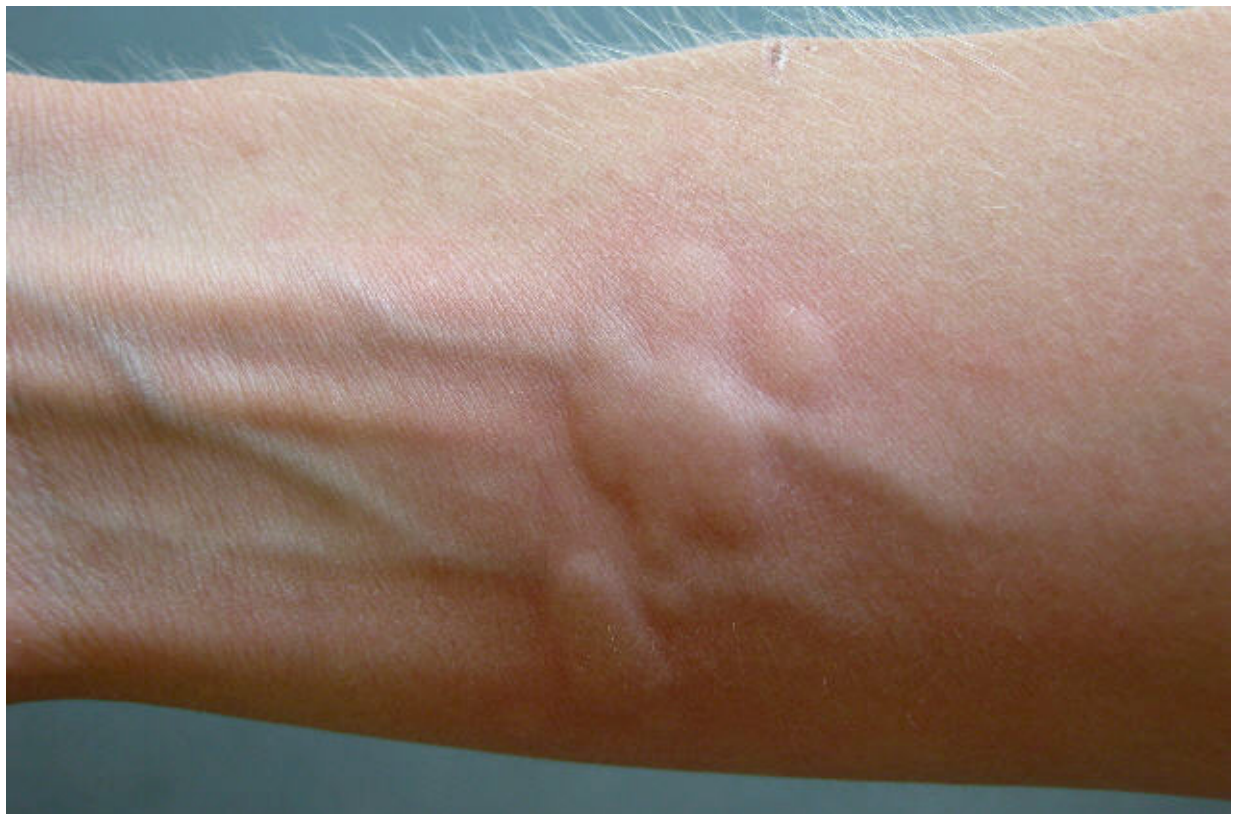Figure 1. *Uraba lugens* caterpillars (Photo courtesy of Ensis)



Exposure, symptoms of envenomation, and possible treatment

The exposure of people to stinging caterpillars is greater when these creatures are occurring at high densities, as numerous caterpillars may be found in the direct vicinity of an infested tree. Large infestations of stinging caterpillars can become a serious public health issue, and in some severe cases it has led to the closure of schools.²

Figure 2. Wheals formed approximately 30 minutes after exposure to the urticating spines of *Uraba lugens* (Photo courtesy of Ensis)



Most cases of harmful exposure to caterpillars seem to occur in young children, and in one study of 365 cases of exposure to *Lophocampa caryae* Harris (Lepidoptera: Arctiidae), 80% of the records were paediatric exposures.¹¹ Caterpillars are a source of curiosity to children due to their easy accessibility and slow mobility,¹¹ and also due to these creatures' generally bright colours. Young children tend to have thinner skin and smaller bodies than adults, both of which may increase the extent of the reaction.¹²

Approximately 150 species of Lepidoptera from more than a dozen families have been described to cause some form of injury to humans.^{1,13} The caterpillars of many species have chitinous spines that are capable of penetrating human epidermis, and injecting venom parenterally.¹³ Exposure to stinging caterpillars can result in a variety of reactions, which vary according to the species,¹⁴ but adverse reactions range from

moderate to severe local effects, usually characterised by severe pain, and less commonly systemic effects,¹⁴ including renal failure and intracerebral hemorrhage.¹

The nature of *U. lugens* venom is largely unknown,¹² but it contains histamine and most likely also a proteinaceous substance.³ Skin contact with the envenomating bristles of *U. lugens* will immediately cause a sharp stinging sensation, which may be severe.³ Local pain is followed by the associated formation of flat itching wheals (Figure 2),¹⁵ which may remain visible for a few weeks.³

The skin reaction may cause a high degree of discomfort, and an adult woman described the reaction as “violent and distressful for 3–4 days”.³ As a result, adverse reactions to *U. lugens* venom may be particularly distressing for young children. It is important to note that even the spines on the youngest caterpillars are capable of stinging, and that these continue to sting even after the insect is dead, and also following the shedding of skin.³

Ingestion of caterpillars of other species by children has been described in the literature,^{1,14,16} with some adverse effects consisting of pain, difficulty swallowing, drooling, and shortness of breath.¹⁶ There seem to be no records of *U. lugens* ingestion, but it would be likely to require hospitalisation. While life-threatening reactions are unlikely to occur, the possibility of serious adverse reactions, such as anaphylaxis, cannot be discarded.¹² Although severe and systemic reactions to *U. lugens* have not been described, eye lesions could be potentially serious and should be dealt with by a specialist. Note that there is no evidence of sensitisation from repeated exposures to *U. lugens*.³

Contact with some caterpillar species such as the white-stemmed gum moth (*Chelepteryx collesi*) leads to a very large number of hairs becoming embedded in the skin.¹⁷ Even though for some species attempts to remove the hairs seem to be unsuccessful,¹⁷ the careful removal of spine(s) with adhesive tape is a commonly prescribed initial treatment of urticating caterpillar stings.^{2,14} However, this is not likely to be an issue with *U. lugens*, as there seem to be no reports of its spines becoming embedded in human skin, especially in Southcotts’s detailed descriptions of numerous cases of exposure.³ Instead, the application of ice packs, and oral or topical administration of antihistamines to attenuate itching and burning sensation, is advised.^{1,2,14} Intense inflammatory reaction may be locally relieved by topical or oral corticosteroids.^{1,2}

Current incidence and recommendations

There are no available data on the incidence of exposure to *U. lugens* in New Zealand. Biosecurity New Zealand has information on at least two confirmed cases, where members of the public have contacted the agency following adverse reactions to an ‘unknown’ caterpillar (Mark Ross, personal communication; 2006). However, based on the distribution of the caterpillars in the Auckland region and its relatively high density in some areas, one could expect the actual number of cases to be considerably higher. The author would welcome information on any confirmed cases of exposure to *U. lugens* in New Zealand.

Even though *U. lugens* is the target of a long-term management programme, this species is well-established in the Auckland region and will not be eradicated. Since Auckland is the most populated region in the country, human exposure to the

caterpillars is likely to occur on a regular basis, particularly among children. As a result, general practitioners should consider exposure to *U. lugens* in the differential diagnosis of contact dermatitis, where symptoms such as wheals are present.

Prevention is an important tool, and in cases where exposure to *U. lugens* is confirmed, the access of children to areas adjacent to infested trees should be restricted, and a reputable pest controller should be contacted for mitigating action. In case the infested tree is located on public land, the local or regional authority should be notified.

Avoidance is a fundamental preventive tool, and children should be educated not to touch or handle *U. lugens* caterpillars. It should be also noted that this species' potential establishment in *Eucalyptus* plantations in New Zealand may lead to occupational safety and health concerns, as a result of the likelihood of exposure to forestry workers.¹²

Author information: José G B Derraik, Advisor (Human Health), Risk Analysis Group, Pre-Clearance Directorate, Biosecurity New Zealand, Wellington

Acknowledgements: I thank John Fountain (National Poisons Centre, University of Otago), Doug Lush (Ministry of Health), and Ian Gear and Mark Ross (Biosecurity New Zealand) for revising this manuscript and providing valuable feedback. Ensis Forest Biosecurity & Protection has kindly allowed their photographs to be included in this article. Thanks also to Brian Patrick (Otago Museum) for input.

Correspondence: José G B Derraik, Biosecurity New Zealand, PO Box 2526, Wellington. Fax: (04) 894 0733; email: jose.derraik@maf.govt.nz

References:

1. Diaz JH. The evolving global epidemiology, syndromic classification, management, and prevention of caterpillar envenoming. *Am J Trop Med Hyg.* 2005;72:347–57.
2. Goddard J. Physician's guide to arthropods of medical importance. 4th ed. Boca Raton: CRC Press; 2003.
3. Southcott RV. Lepidopterism in the Australian region. *Rec Adelaide Children's Hosp.* 1978;2:87–173.
4. Potter KJB, Stephens AEA. Suitability of valued eucalypt species for the larval development of the gum leaf skeletoniser, *Uraba lugens*. *N Z Plant Prot.* 2005;58:184–90.
5. Phillips C. Gum leaf skeletonizer – *Uraba lugens* Walker. *Forest Insects.* 1992;16. Available online. URL: http://www.forestry.sa.gov.au/privateforestry/insect_fact_sheets/Fact_Sheet_html/FHS%2016%20Gumleaf%20skeletonizer.htm Accessed August 2006.
6. Ross M. Gum leaf skeletoniser found in Onehunga. *Biosecurity.* 2003;41:6.
7. Suckling DM, Gibb AR, Dentener PR, et al. *Uraba lugens* (Lepidoptera: Nolidae) in New Zealand: pheromone trapping for delimitation and phenology. *J Econ Entomol.* 2005;98:1187–92.
8. Ross M. Gum leaf skeletoniser long-term management approved. *Biosecurity.* 2003;47:8.
9. Ross M. Gum leaf skeletoniser: long-term management programme producing results. *Biosecurity.* 2004;53:12.
10. Mansfield S, Kriticos DJ, Potter KJB, Watson MC. Parasitism of gum leaf skeletoniser (*Uraba lugens*) in New Zealand. *N Z Plant Prot.* 2005;58:191–6.

11. Kuspis DA, Rawlins JE, Krenzelok EP. Human exposures to stinging caterpillar: *Lophocampa caryae* exposures. *Am J Emerg Med.* 2001;19:396–8.
12. Aer’ aqua Medical Services. Report on health effects on exposure to gum leaf skeletoniser urticating hairs: Unpublished report prepared for the Ministry of Agriculture and Forestry; 12 May 2004.
13. Vega ML, Vega J, Vega JM, et al. Cutaneous reactions to pine processionary caterpillar (*Thaumetopoea pityocampa*) in pediatric population. *Pediatr Allergy Immunol.* 2003;14:482–6.
14. Balit CR, Geary MJ, Russell RC, Isbister GK. Prospective study of definite caterpillar exposures. *Toxicon.* 2003;42:657–62.
15. Southcott RV. Some harmful Australian insects. *Med J Aust.* 1988;149:656–62.
16. Lee D, Pitetti RD, Casselbrant ML. Oropharyngeal manifestations of lepidopterism. *Arch Otolaryngol Head Neck Surg.* 1999;125:50–2.
17. Balit CR, Geary MJ, Russell RC, Isbister GK. Clinical effects of exposure to the white-stemmed gum moth (*Chelepteryx collesi*). *Emerg Med Australasia.* 2004;16:74–81.
18. Berndt L. Gumleaf skeletoniser – potential for biological control. *Biosecurity.* 2006;69:13.